



A case series on disorder on psychiatric symptoms in epileptic patients with emphasis on the disorder of awareness of body

Abstract

Background: Paroxysmal psychiatric symptoms are commonly associated with pre-ictal, ictal, or post-ictal phases of seizure. Most of the studies regarding psychiatric symptoms are semiological in nature emphasising anatomical correlates of seizure in patients in pre-neurosurgical evaluation. Phenomenological studies of psychiatric symptoms in epilepsy are limited by various factors. **Objective:** To describe and evaluate phenomenological understanding of ictal fear and reflex epilepsy in two patients while emphasising their experiences with respect to disorder of awareness of body while also presenting electroencephalogram (EEG), imaging results, and clinical examination of the patients. **Methods and results:** Two case reports of patients attending Department of Psychiatry, Tezpur Medical College and Hospital (TMCH) revealed ictal fear in generalised myoclonic epilepsy in one case and reflex epilepsy in generalised epilepsy syndrome in another case. **Conclusion:** It was concluded that in undiagnosed cases of epilepsy as with the first case, diagnosis of ictal fear is very difficult. Ictal fear in generalised myoclonic seizure as compared to partial seizure such as temporal lobe seizures is not common. Diagnosis of reflex epilepsy in generalised epilepsy syndrome is confused with dissociative phenomenon/conversion syndromes. Phenomenological evaluation of these psychiatric symptoms revealed disorder in awareness of body.

Keywords: Ictal fear. Partial seizures. Temporal lobe epilepsy. Body schema. Reflex epilepsy.

Raj Kumar Seal, Barasha Saharia, Bishruta Goswami, Rima Phukan

Department of Psychiatry, Tezpur Medical College and Hospital, Tezpur, Assam

Correspondence: Dr. Raj Kumar Seal, Assistant Professor, Department of Psychiatry, Tezpur Medical College and Hospital, Tezpur, Assam, India. PIN-784010. sealraj2007@gmail.com

Received: 22 December 2022

Revised: 21 January 2023

Accepted: 29 March 2023

Epub: 11 April 2023

DOI: 10.5958/2394-2061.2022.00010.6

INTRODUCTION

There are two aspects to our bodies, body as an object and body as subjectively felt.[1] Epileptic patients have many paroxysmal psychiatric symptoms (pre-ictal, ictal, and post-ictal) that differ subjectively from similar psychiatric disturbances such as hypochondria, conversion, and so on. Ictal fear is one of the common epileptic auras. Sometimes, it is the sole or predominant manifestation of simple partial seizures or the initial expression of a complex partial seizure. It has been semiologically correlated in patients with mesial temporal lobe epilepsy, probably associated with mesial temporal structures like the amygdala, peri-amygdaloid, and hippocampal stimulation. It typically manifests as a sudden subjective feeling of fearfulness, lasting from 30-60 seconds which may closely mimic panic attacks, at the beginning of or during an epileptic seizure without any context or any relation to a precedent causal perception or cognition.[2] Retrospectively many cases of suicide in epileptic patients postulated due to multiple psychosocial factors including ictal fear have been documented in studies. Reflex epilepsy is the term used for epileptic seizures which occur in response

to some specific precipitating factors like touch, sound, etc.[3] The precipitating factors may be extrinsic or intrinsic (e.g., movement, thinking, etc.). Reflex seizures may be generalised, absences, generalised tonic-clonic seizures, or focal. They are confused with dissociative or conversion phenomenon. We will discuss and elaborate on the phenomenology of such disturbances in this case series.

CASE REPORT-1

A 45 years old married female, hailing from a rural background of low socioeconomic status, presented at the Casualty Department of Tezpur Medical College and Hospital, Tezpur, Assam, India with an alleged history of suicide by deliberate overdose of prescribed antipsychotic sedative medication at her own residence. The patient was sedated at the time of the presentation. She was admitted to the female medicine ward for observation. She was sent to psychiatry outpatient department (OPD) the next day for a detailed evaluation. On evaluation, it was found that the patient was having euthymic mood and affect, and no death wishes, but she acknowledged a sudden suicidal idea to her

mind associated with depressive cognition, hopelessness, helplessness, and worthlessness which led her to do this act impulsively. She stated that she would probably be unable to control such impulsive behaviour if the same thought were to cross her mind again. The patient also complained of episodic tremulousness in both hands for the past several years and for the past three months, she has had sudden brief shock-like sensations of the body involving the hands. The patient and the informant gave a history of falling off objects from her hands often following these episodes. Once when she was chopping vegetables, she got her fingers cut due to these shock-like jerks. The patient was then shifted to the psychiatry ward and an electroencephalogram (EEG) was done. EEG showed bilateral slow wave complexes with alteration of background rhythm, more predominantly on bilateral temporoparietal region suggestive of epileptiform discharges (Figure 1). On neurological evaluation, the patient had coarse tremors in both hands, a normal deep tendon reflex, bilateral plantar flexor response, and a non-contrast computerised tomography (CT) scan of brain that revealed no notable abnormalities. The patient was given a provisional diagnosis of generalised myoclonic seizure with an aura of ictal fear. She was prescribed anticonvulsant medication, levetiracetam 1000 mg/day and antidepressant, escitalopram 10 mg/day, and she responded quickly to treatment.

CASE REPORT-2

A 31 years old male, with no formal education, from a lower socioeconomic status and rural background, diagnosed case of childhood-onset epilepsy, generalised tonic-clonic seizure (GTCS) was referred to the psychiatry ward for new onset behavioural disturbances from the Ear, Nose, and Throat (ENT) department where he was treated for Ludwig's angina (Figure 2). According to the father, for last three months, he

has a sudden swing at the left forelimb and remains suspended in that position till someone comes near or touches him, which led him to a complete generalised tonic-clonic seizure and loss of consciousness. After regaining consciousness, he has no memory of the event. He was previously diagnosed as a case of Sturge-Weber syndrome with seizure. He was on medication, sodium valproate 1000 mg/day, phenobarbitone 60 mg/day, and olanzapine 5 mg/day. He was a product of spontaneous vaginal delivery assisted with forceps. He had delayed developmental milestones and could study till class VII. His CT brain report showed right-sided hemispheric atrophy with Sturge-Weber syndrome. His cranial nerve examination and motor system examination was normal. His mental status examination did not reveal any thought or perceptual disorder. No cogwheel rigidity or extrapyramidal signs were noted. His EEG was uneventful except for theta slowing of background (Figure 3). His new behaviour/phenomenon was diagnosed as reflex seizures in generalised epilepsy syndrome.[3] The precipitating stimuli is classified as somatosensory stimuli. His phenobarbitone dose was increased to 90 mg/day which caused remission of symptoms.

DISCUSSION

Electrical brain stimulation in neurosurgery patients who are awake can cause a wide range of sensations, emotions, and cognitions. These mental phenomena have primarily been considered in terms of functional localisation within the human brain in both physiology and disease.[4] There are certain conditions in which disorder in body schema occurs as a part of the epileptic phenomenon. Often such conditions are associated with fear, depersonalisation, or dissociation/conversion. They are frequently misunderstood and misdiagnosed. Often a phenomenological approach in

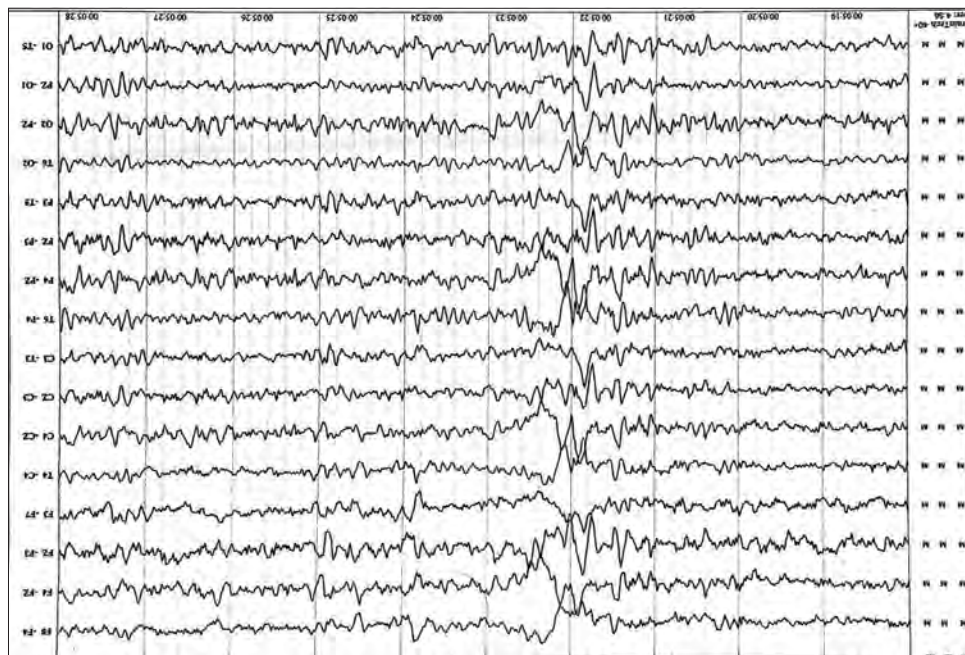


Figure 1: Case 1 electroencephalogram (EEG) showing bilateral slow wave complexes with alteration of background rhythm, predominated in temporo-parietal region.

understanding such phenomenon is limited as well as it does not include phenomenological investigation of disorders in terms of body awareness disorders.

Our first case of ictal fear on phenomenological investigation revealed some important features. Firstly, most cases of ictal fear who attempt suicide have partial amnesia due to the mode of suicide like hanging or cut throat injury which cause hypoxic encephalopathy. Our case had a very lucid recollection of her experience which makes it a very good material for detailed phenomenological investigation. Secondly, she recollected that a sudden overwhelming feeling of fear and suicide together, and her whole body became inhospitable for her. This embodied experience was at variance with panic attack, where increase in symptoms' magnitude or increasing involvement of body parts are seen. She was not preoccupied with the fear as seen in

panic attack. The patient's ictal fear was qualitatively and temporally different from panic which led to misdiagnosis of psychosis in her case from a different psychiatric establishment. Third important feature was that rather than seeking relief by seeking company or help, our patient had no recluse and sought relief by act of suicide itself. The alien and inhospitable nature of her own body during ictal fear is a differentiating point to be kept in mind while investigating such phenomenon. Electrical stimulation of the hippocampus or amygdala has been shown to induce fear in epileptic patients.[5] This evoked fear sensation often differs significantly from that of a panic attack as we have seen in our case.[6] It is always difficult to diagnose ictal fear in patients without a prior diagnosis of seizure as in our case. Analysis of motor symptoms such as periodic jerks as in our case can help in diagnosing seizure in such cases.

In our second case of reflex epilepsy, the neuroanatomical area of reflex was increased to whole body in which tactile stimulation and convulsions/jerks have become associated. The expansion of area of stimulation from dermatomes to any part of body can be understood as diffusion of body schema transiently. So, we see that such presentation is very similar to dissociative phenomenon but alteration of her antiepileptic medication, namely increasing the dose led to abolition of symptoms abruptly.[7]

Our study therefore showed that phenomenological understanding of these experiences could pave way for open-minded therapeutic interventions. It raises the possibility of investigating whether the use of means to abort such pre-ictal phenomenon will result ultimately in aborting the seizure itself. It also raises the possibility of investigating techniques like induction of sleep/narcosis by benzodiazepines or alternative therapies like fixing on an attention focus, yoga to be tested in such patients.[8]

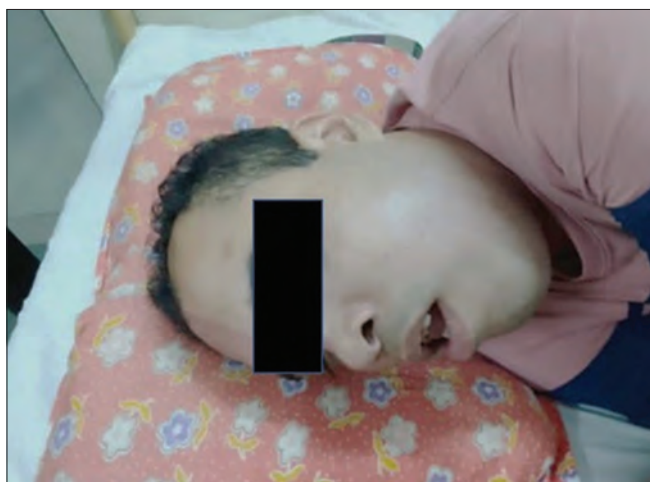

Figure 2: Photograph of the patient (case 2) of Sturge-Weber syndrome with Ludwig's angina.

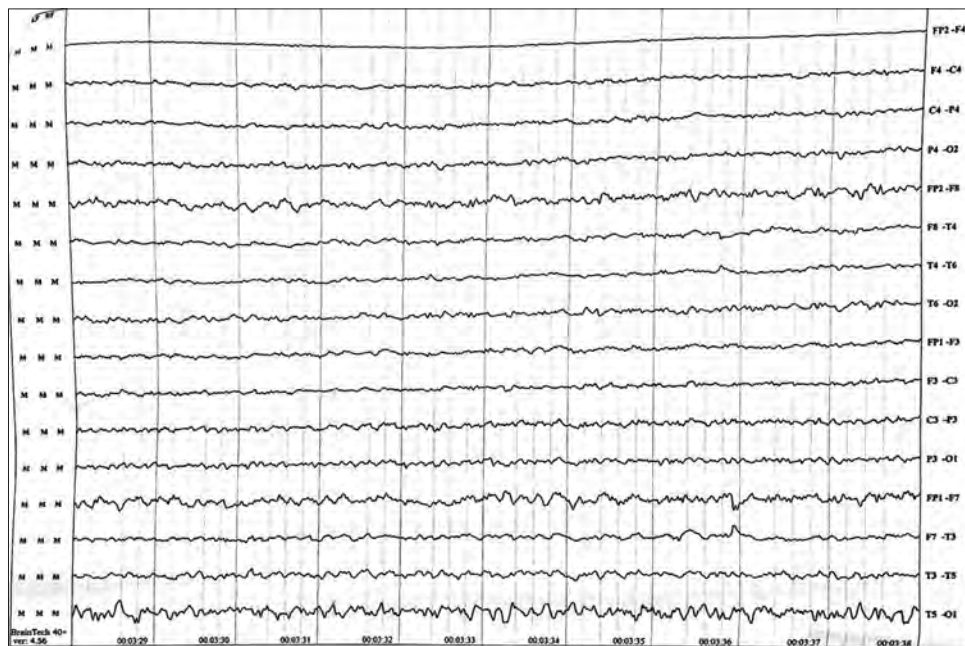


Figure 3: Case 2 electroencephalogram (EEG) showing theta slowing background with fronto-temporal slow wave.

Declaration of patient consent

The authors certify that they have obtained all appropriate patient consent forms. In the form, the patient has given his/her consent for his/her images and other clinical information to be reported in the journal. The patient understands that his/her name and initials will not be published and due efforts will be made to conceal identity, but anonymity cannot be guaranteed.

REFERENCES

1. Sims A. Symptoms in the mind: an introduction to descriptive psychopathology. Bailliere Tindall Publishers; 1988.
2. Rosa VP, Araújo Filho GM, Rahal MA, Caboclo LO, Sakamoto AC, Yacubian EM. Ictal fear: semiologic characteristics and differential diagnosis with interictal anxiety disorders. *J Epilepsy Clin Neurophysiol.* 2006;12:89-94.
3. Lishman WA. Epilepsy in organic psychiatry: the psychological consequences of cerebral disorder. Oxford: Blackwell Science; 2008.

4. Engel J Jr. ILAE classification of epilepsy syndromes. *Epilepsy Res.* 2006;70 Suppl 1:S5-10.
5. Halgren E, Walter RD, Cherlow DG, Crandall PH. Mental phenomena evoked by electrical stimulation of the human hippocampal formation and amygdala. *Brain.* 1978;101:83-117.
6. Biraben A, Taussig D, Thomas P, Even C, Vignal JP, Scarabin JM, *et al.* Fear as the main feature of epileptic seizures. *J Neurol Neurosurg Psychiatry.* 2001;70:186-91.
7. Gloor P, Olivier A, Quesney LF, Andermann F, Horowitz S. The role of the limbic system in experiential phenomena of temporal lobe epilepsy. *Ann Neurol.* 1982;12:129-44.
8. French JA, Williamson PD, Thadani VM, Darcey TM, Mattson RH, Spencer SS, *et al.* Characteristics of medial temporal lobe epilepsy: I. Results of history and physical examination. *Ann Neurol.* 1993;34:774-80.

Seal RK, Saharia B, Goswami B, Phukan R. A case series on disorder on psychiatric symptoms in epileptic patients with emphasis on the disorder of awareness of body. *Open J Psychiatry Allied Sci.* 2022;13:96-9. doi: 10.5958/2394-2061.2022.00010.6. Epub 2023 Apr 11.

Source of support: Nil. Declaration of interest: None.